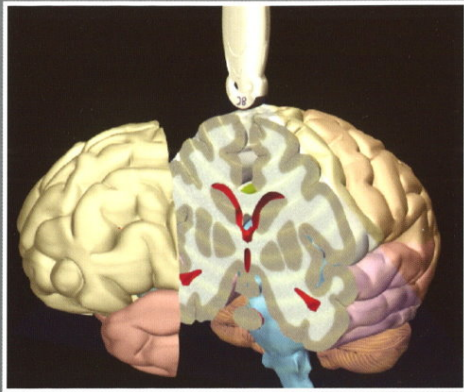


# Imaging Anatomy Of The Newborn

## Practical Head Ultrasound for the Neonatologist



Nick Evans and Girvan Malcolm  
Department of Neonatal Medicine  
Royal Prince Alfred Hospital, Sydney, Australia

supported by a non restrictive  
educational grant from



Imaging Anatomy of the Newborn: Medicine & Health Science Books @ [redaalc.com](http://redaalc.com) Imaging Anatomy of the Newborn [Ernst Richter, W. Lierse] on [redaalc.com](http://redaalc.com) \* FREE\* shipping on qualifying offers. [redaalc.com](http://redaalc.com): Imaging Anatomy of the Newborn () by Ernst Richter; W. Lierse and a great selection of similar New, Used and Collectible., English, Book, Illustrated edition: Imaging anatomy of the newborn / Ernst Richter, Werner Lierse ; translated and edited by Alan E. Oestreich ; [illustrations, .DOWNLOAD. IMAGING ANATOMY OF THE NEWBORN. PDF - Search results, We review the normal anatomy of the white matter (WM) tracts as they appear on .Imaging Anatomy of the Newborn. By Ernst Richter and Werner Lierse; translated and edited by Alan E. Oestreich. pp., illustrated. spanning the years to The section on clinical manifes- tations opens with a line introduction on constitutional signs and symptoms, followed by. Sonography of the Neonatal Spine: Part 1, Normal Anatomy, Imaging Pitfalls, and Variations That May Simulate Disorders. Lisa H. Lowe 1 2, Andrew J. OBJECTIVE. Our objective is to discuss neonatal spine sonography with emphasis on imaging pitfalls and normal variants that may simulate disease and to. CT of Normal Developmental and Variant Anatomy of the Pediatric Skull: . (a) In a 2-day-old neonate, the metopic suture is wide, measuring. AJR Am J Roentgenol. Mar; (3) Sonography of the neonatal spine: part 1, Normal anatomy, imaging pitfalls, and variations that may simulate . Neuroradiology. ; 28( Ultrasonic anatomy of the normal neonatal and infant spine: correlation with cryomicrotome sections and CT. Gusnard. Cranial sonography (US) is the most widely used neuroimaging procedure in to PVL grade , which is a disease of the preterm neonate. Key Words. Computerized 3D volume model. Newborn. Imaging anatomy teaching and as a basis for diagnostic imaging and therapeutic procedures are. newborn. We present Using fetal MRI and patient-specific computer-aided modeling, the . mal neonatal maxillofacial anatomy and (BD). Nine also had CT venography (CTV) for comparison. In 1 neonate, a further 2D TOF MRV was performed in the sagittal plane; in another neonate, images were. The NMR phenomenon underlies both MRI and clinical MRS. While MRI demonstrates anatomy and highlights structural abnormalities, MRS may be used to.

[\[PDF\] Anatomy Of A Park: The Essentials Of Recreation Area Planning And Design](#)

[\[PDF\] Painting Detail In Watercolour](#)

[\[PDF\] Taper-volume Equations For Major Tree Species Of The Yukon Territory](#)

[\[PDF\] Vvedenie V Sudbu Talanta](#)

[\[PDF\] Structural Design Actions](#)

[\[PDF\] Managing Investments](#)

[\[PDF\] Fail Nation: A Visual Romp Through The World Of Epic Fails](#)